

Subthreshold diode micropulse laser versus observation in acute central serous chorioretinopathy

Clin Exp Optom 2019; 102: 79–85

DOI:10.1111/cox.12818

Supriya Arora* MS DNB FICO FAICO

Preethi Sridharan† MS

Tarun Arora* MD DNB FICO

Mohit Chhabra† MBBS

Basudeb Ghosh† MD MNAMS

*Department of Ophthalmology, Princess Margaret Hospital, Nassau New Providence, Bahamas

†Guru Nanak Eye Centre, Department of Ophthalmology, Maulana Azad Medical College, Maharaja Ranjit Singh Marg, New Delhi, India
E-mail: supriyaaroragnc@hotmail.com

Submitted: 17 May 2018

Revised: 24 June 2018

Accepted for publication: 2 July 2018

Background: The purpose of this study was to evaluate subthreshold diode micropulse (SDM) laser as a treatment modality in acute central serous chorioretinopathy (CSC) and compare it with the current standard of care (observation).

Methods: A randomised controlled trial was conducted on 68 eyes (34 eyes in SDM laser group and 34 eyes in observation group) with acute CSC, with a single angiographic leak and duration of complaints less than two months. Detailed history, examination and investigations were performed at the baseline and at regular intervals until six months.

Results: Eyes in the laser group had significantly higher best-corrected visual acuity at two weeks ($p = 0.002$), four weeks ($p < 0.001$), eight weeks ($p < 0.001$), 16 weeks ($p = 0.042$) and six months ($p = 0.008$), and higher contrast sensitivity at eight weeks ($p = 0.008$), 16 weeks ($p < 0.001$) and six months ($p < 0.001$). A recurrent/persistent neurosensory detachment was observed at the end of six months in 11.76 per cent of SDM laser treated eyes versus 29.41 per cent of eyes in the observation group ($p = 0.036$).

Conclusion: SDM laser produces faster and superior visual rehabilitation without any adverse effects. It also reduces the chances of CSC going into chronicity and recurrence compared to the current standard of care (observation).

Key words: central serous chorioretinopathy, choroidal thickness, micropulse diode laser, neurosensory detachment, subthreshold laser

Central serous chorioretinopathy (CSC) is characterised by serous detachment of the neurosensory retina caused by focal leakage of fluid from the choroid to the subretinal space, due to impairment in the barrier function of the retinal pigment epithelium.^{1,2} CSC is mostly self-limiting, as 80 per cent of cases resolve spontaneously within six months, reaching a visual acuity of $> 6/9$.³ Therefore, the current standard of care for acute CSC is observation.

Treatment is indicated for chronic or recurrent CSC. Various treatment options such as photodynamic therapy,^{4,5} laser photocoagulation^{6,7} and subthreshold diode micropulse (SDM) laser^{8,9} are available. However, fluid accumulation under the retina at the acute stage of the disease seems to cause a certain amount of damage to the photoreceptors, which seems to persist even after the fluid is reabsorbed. The disease results in diminished contrast sensitivity, which can be permanent and leave the patient visually impaired.¹⁰

Hata et al.¹¹ showed that in CSC, outer nuclear layer thinning starts in the early stage and may continue as long as the

subretinal fluid persists. Outer nuclear layer thinning at the central fovea should indicate cone photoreceptor loss, considering the distribution of rod and cone photoreceptors. Gawecki et al.¹² used SDM laser for treatment of chronic CSC and demonstrated that although the laser provided good morphological results, there was no significant improvement in visual acuity. They concluded that in order to achieve good visual results, SDM laser should be considered in acute cases.

Therefore, treatment options for acute CSC must be explored so as to avoid permanent damage to photoreceptors. However, the most important consideration for treating acute CSC is safety, or lack of side effects by the treating modality.

The present study evaluated the role of SDM laser in treating acute CSC compared with the current standard of care (observation).

Methods

This was a randomised controlled trial on 68 eyes of 68 consecutive patients with

acute CSC, carried out at Guru Nanak Eye Centre, Maulana Azad Medical College, New Delhi, from September 2013 to August 2016. The study was performed in accordance with the tenets of the Declaration of Helsinki and approved by the institutional review board.

Inclusion criteria were: duration of symptoms less than two months; single active angiographic leak (foveal/juxtafoveal/extrafoveal); subretinal fluid involving the fovea on spectral domain optical coherence tomography; first episode of CSC; and absence of any other ocular disease. Patients who had a history of taking steroids and those who had undergone intraocular surgery, including retinal laser treatment, were excluded. Patients in whom fluorescein angiography was contraindicated were also excluded. Written informed consent was obtained from all patients before inclusion in the study.

Detailed history and examination, including best-corrected visual acuity, contrast sensitivity (Functional Acuity Contrast Testing chart), Amsler grid charting, fundus examination using slitlamp 90 D

biomicroscopy, and indirect ophthalmoscopy were performed. Visual acuity was assessed on a Snellen chart and converted to logMAR units for statistical analysis.

Investigations included fundus fluorescein angiography (VISUCAM 500; Carl Zeiss, New Delhi, India), spectral domain optical coherence tomography (Nidek RS 3000 Advance; Nidek Co. Ltd., Gamagori, Japan) and visual fields (10-2) (Humphrey Automated Visual Field Test). All tests were performed at baseline and at two, four, eight and 16 weeks, and six months. Parameters that were evaluated on spectral domain optical coherence tomography included height and width of neurosensory detachment and choroidal thickness. Maximum height and width of the neurosensory detachment was measured manually using a calliper on spectral domain optical coherence tomography images.

For measuring choroidal thickness, the following protocol was adopted.¹³ The choroid was imaged in the macular line protocol by positioning the spectral domain optical coherence tomography instrument close enough to the eye to obtain an inverted image (choroidal mode, choroidal intensity +5). Software analysis segmentation of 6 + 1 retinal layers enables the manual drawing of a line to form one additional layer, aside from the automatically formed six layers, in a high definition optical coherence tomography image. Choroidal thickness was measured as the perpendicular distance between the automated retinal pigment epithelium line and the manually drawn line at the choriocleral interface.

Four sections (each comprised of 120 averaged scans) were captured for each eye in four different directions: horizontal, vertical, 45° and 135°. Choroidal thickness measurements were recorded at nine points in each scan (centre of the fovea, 300 µm temporal

and nasal to the fovea; 600 µm temporal and nasal to the fovea; 900 µm temporal and nasal to the fovea; and 1,200 µm temporal and nasal to the fovea). Thus, for each eye, 36 measurements (nine points in each scan × four scans in different directions) were obtained. An average of these 36 measurements was taken to be the choroidal thickness in the parafoveal area ($C_{\text{parafoveal}}$) for each eye. Subfoveal choroidal thickness was measured four times in each eye: along the horizontal scan, vertical scan, and two oblique scans. An average of these four values was taken as $C_{\text{subfoveal}}$ for each eye.

Eligible eyes were randomised into two groups using a centralised computer-generated randomisation list. All patients in the SDM laser group (Group A) were treated using an 810-nm infrared diode laser (Oculight SLX; Iridex Corp, Mountain View, California, USA), as per the technique described by Koss et al.⁹ In Group A, the minimum threshold power (P) for a light visible burn was determined by applying a test burn in the nasal mid-periphery (continuous wave emission mode, 125 µm spot size, 200 ms exposure duration). After determination of P, the laser mode was changed from continuous wave to micropulse emission at 15 per cent duty cycle and the power was doubled (2P) in micropulse emission mode.

Each laser envelope consisted of one hundred 300 µs micropulses, delivered over two milliseconds (300 µs on and 1,700 µs off). About 100 pulse envelopes were applied at the leaking point. Steps were taken to ensure that the SDM laser treatment was 'invisible by biomicroscopy', meaning laser treatment was not clinically discernable, on fundus fluorescein angiography, fundus autofluorescence or on spectral domain optical coherence tomography. Great care was taken if the colour of the retinal

pigment epithelium changed during the laser treatment, prompting immediate cessation of laser application.

Eyes in the observation group (Group B) received no intervention and were followed up as per our follow-up protocol.

Persistence of neurosensory detachment and recurrence of neurosensory detachment in both groups were recorded.

Results

Mean age of patients in the SDM laser group was 35.05 ± 2.53 years and in the observation group was 36.35 ± 6.38 years (p = 0.132). Males constituted 82.35 ± 17.65 per cent versus 91.18 ± 8.82 per cent in the laser and observation groups, respectively (p = 0.142). Duration of symptoms was 35.47 ± 10.64 days in the laser group and 39.26 ± 9.78 days in the observation group (p = 0.065).

Best-corrected visual acuity in the laser group as well as in the observation group increased significantly (p < 0.001) at two, four, eight and 16 weeks, and six months, compared to the baseline.

The two groups were matched in terms of best-corrected visual acuity at baseline (p = 0.427), but the laser group had significantly higher best-corrected visual acuity at two (p = 0.002), four (p < 0.001), eight (p < 0.001) and 16 weeks (p = 0.042), and six months (p = 0.008) (Table 1).

Contrast sensitivity (logMAR) at baseline was 1.14 ± 0.27 in the laser group and 1.04 ± 0.37 in the observation group (p = 0.123). Contrast sensitivity increased significantly at each visit (p < 0.001) compared to baseline in the laser group as well as in the observation group. The laser group had significantly higher contrast sensitivity

Visual acuity in logMAR	Baseline	2 weeks	4 weeks	8 weeks	16 weeks	6 months
Laser						
Mean	0.59	0.27	0.14	0.06	0.04	0.03
SD	±0.27	±0.2	±0.1	±0.09	±0.09	±0.08
p-value (versus baseline)		< 0.001	< 0.001	< 0.001	< 0.001	< 0.001
Observation						
Mean	0.60	0.40	0.25	0.17	0.09	0.14
SD	±0.21	±0.16	±0.12	±0.15	±0.14	±0.24
p-value (versus baseline)		< 0.001	< 0.001	< 0.001	< 0.001	< 0.001
p-value (laser versus observation)	0.427	0.002	< 0.001	< 0.001	0.042	0.008

Table 1. Comparison of laser group versus observation group in terms of best-corrected visual acuity over time

Contrast sensitivity	Baseline	2 weeks	4 weeks	8 weeks	16 weeks	6 months
Laser						
Mean	1.14	1.29	1.39	1.56	1.65	1.65
SD	±0.27	±0.25	±0.32	±0.17	±0.22	±0.23
p-value (versus baseline)		< 0.001	< 0.001	< 0.001	< 0.001	< 0.001
Observation						
Mean	1.04	1.24	1.29	1.46	1.48	1.45
SD	±0.37	±0.22	±0.24	±0.17	±0.17	±0.2
p-value (versus baseline)		< 0.001	< 0.001	< 0.001	< 0.001	< 0.001
p-value (laser versus observation)	0.123	0.173	0.081	0.008	< 0.001	< 0.001

Table 2. Comparison of laser group versus observation group in terms of contrast sensitivity (Functional Acuity Contrast Testing chart) over time

compared to the observation group at eight ($p = 0.008$) and 16 weeks ($p < 0.001$), and six months ($p < 0.001$) (Table 2).

The height of neurosensory detachment was matched between the two groups at baseline ($p = 0.078$). It was significantly higher in the observation group at two ($p = 0.021$), four ($p = 0.002$) and eight weeks ($p < 0.001$), and six months ($p = 0.022$), compared to the laser group (Table 3). The width of the neurosensory detachment was matched between the two groups at the baseline ($p = 0.439$). The observation group had significantly greater width at eight weeks ($p < 0.001$) and six months ($p = 0.032$) compared to the laser group.

In the laser group, subfoveal choroidal thickness ($C_{\text{subfoveal}}$) was $410 \pm 80.49 \mu\text{m}$ at the baseline. It decreased significantly ($p < 0.001$) at two, four, eight and 16 weeks, and six months. In the observation group, $C_{\text{subfoveal}}$ was $416.83 \pm 67.87 \mu\text{m}$ at baseline, and decreased significantly ($p < 0.001$) at two, four, eight and 16 weeks, and six months. $C_{\text{subfoveal}}$ was matched between the two groups at baseline ($p = 0.369$) and

significantly lower in the laser group at eight ($p = 0.030$) and 16 weeks ($p = 0.049$), and six months ($p < 0.001$).

Parafoveal choroidal thickness ($C_{\text{parafoveal}}$) was matched between the two groups at baseline ($p = 0.270$). It decreased significantly ($p < 0.001$) in the laser group at two, four, eight and 16 weeks, and six months, and it also decreased significantly in the observation group ($p < 0.001$) at two, four, eight and 16 weeks, and six months, compared to baseline. The laser group had a significantly lower $C_{\text{parafoveal}}$ at four ($p = 0.014$), eight ($p < 0.001$) and 16 weeks ($p = 0.0001$), and six months ($p < 0.001$) (Table 4).

At six months, on Amsler grid testing, 17.65 per cent of patients in the laser group versus 38.24 per cent of patients in the observation group ($p = 0.029$) had persistent metamorphopsia. A recurrent/persistent neurosensory detachment was observed at the end of six months in 11.76 per cent of the laser treated eyes versus 29.41 per cent of eyes in the observation group ($p = 0.036$). No visual field abnormalities were noted in either of the groups. No laser-induced iatrogenic

damage (clinically, on fundus fluorescein angiography, on fundus autofluorescence, or on spectral domain optical coherence tomography) was noted in any eye that underwent SDM laser.

Discussion

Many studies have demonstrated the efficacy of conventional laser photocoagulation^{6,7} and photodynamic therapy^{4,5,7} in CSC. Side effects of conventional laser photocoagulation include stimulation of choroidal neovascularisation, localised scotoma, and enlargement of the pigment epithelial atrophic scar over time.^{14,15} Side effects of photodynamic therapy include retinal pigment epithelium atrophy, persistent choriocapillaris hypoperfusion, and secondary choroidal neovascularisation at the treated area.¹⁶⁻¹⁸

Collateral damage invariably occurs in conventional laser photocoagulation because of the energy that is required to produce a visible burn. For this reason, conventional laser

Height of neurosensory detachment in microns	Baseline	2 weeks	4 weeks	8 weeks	16 weeks	6 months
Laser						
Mean	254.53	111.59	38.32	6.12	14.18	15.76
SD	±97.41	±108.79	±37.51	±17.39	±60.21	±69.29
p-value (versus baseline)		< 0.001	< 0.001	< 0.001	< 0.001	< 0.001
Observation						
Mean	288.26	158.53	69.97	42.00	17.12	71.65
SD	±96.65	±73.92	±48.99	±45.26	±43.36	±142.58
p-value (versus baseline)		< 0.001	< 0.001	< 0.001	< 0.001	< 0.001
p-value (laser versus observation)	0.078	0.021	0.002	< 0.001	0.409	0.022

Table 3. Comparison of laser group versus observation group in terms of height of neurosensory detachment over time

Average parafoveal thickness in microns	Baseline	2 weeks	4 weeks	8 weeks	16 weeks	6 months
Laser						
Mean	406.20	378.50	346.48	327.72	324.55	306.79
SD	±76.41	±64.35	±36.42	±23.6	±23.21	±23.27
p-value (versus baseline)		< 0.001	< 0.001	< 0.001	< 0.001	< 0.001
Observation						
Mean	416.73	389.57	370.43	356.01	353.39	358.97
SD	±64.11	±56.1	±50.08	±42.06	±48.66	±47.84
p-value (versus baseline)		< 0.001	< 0.001	< 0.001	< 0.001	< 0.001
p-value (laser versus observation)	0.270	0.226	0.014	< 0.001	0.001	< 0.001

Table 4. Comparison of laser group versus observation group in terms of average parafoveal thickness

cannot be used in acute cases and when the angiographic leak is at a subfoveal location. SDM laser produces the same therapeutic effect as that of a conventional laser without producing a biomicroscopically visible end point. This saves the retinal tissue from structural and functional damage.

Recent hypotheses suggest that the benefits of laser photocoagulation may be derived from the up-and-down regulation of factors mediated by the biological reaction of retinal pigment epithelium cells. This is more likely to occur in retinal pigment epithelium cells that have been only sublethally injured by a lower thermal elevation than at ophthalmoscopically visible endpoints.¹⁹

Successful outcomes using SDM laser have previously been reported in chronic CSC,^{8,20-26} however, there have been very few studies (retrospective and very limited sample size) on acute CSC.^{20,27} Various studies on SDM differ in laser parameters and technique.²⁰⁻³⁰ Duty cycles varying from five per cent^{21,28-30} to 15 per cent^{22,23,27} have been used. Although some studies³¹ have shown that a duty cycle > 10 per cent has been associated with laser-induced damage and that a duty cycle of five per cent is safer, the protocol of this study was designed and approved before 2012. No iatrogenic laser-induced damage was noted in this study and therefore the laser parameters were not altered during the study.

Since SDM laser is believed to be free of side effects,^{20,31-33} the application of this technique was evaluated in this study in acute cases and in cases where the leak was subfoveal. Superior visual rehabilitation in the SDM-treated group was noted as compared to the observation group (best-corrected visual acuity was significantly

better in the SDM laser group from two weeks onward; contrast sensitivity was better in the SDM laser-treated group from eight weeks onward; and there were fewer SDM laser-treated eyes with metamorphopsia at six months).

The above findings could be attributed to faster resolution of subretinal fluid in the laser group compared to the observation group (as evidenced by the significantly lower height of neurosensory detachment in the laser group at two, four and eight weeks, and six months, and a lesser width of neurosensory detachment at eight weeks and six months). At 16 weeks, the difference between the laser group and observation group in terms of height and width of neurosensory detachment was not significant due to the mean being deviated due to a case of recurrent CSC in the SDM laser group.

Another interesting observation was that choroidal thickness in eyes treated with SDM laser was significantly lower compared to the observation group ($C_{\text{subfoveal}}$ was significantly lower in the laser group at eight and 16 weeks, and six months, and $C_{\text{parafoveal}}$ was lower at four, eight and 16 weeks, and six months). Whether lesser choroidal thickness in SDM treated eyes was the cause or the effect of faster resolution of neurosensory detachment still remains to be elucidated.

The pathophysiology of CSC has been attributed to hyperpermeable choroidal vessels^{2,34} impaired choroidal vascular autoregulation and dysfunction of the retinal pigment epithelium barrier and pumping.³⁵

Choroidal thickness is an indirect measure of choroidal hyperpermeability.³⁶

SDM laser causes resolution of CSC by normalisation of retinal pigment epithelium

function and retinal autoregulation by means of sublethal retinal pigment epithelium heat-shock protein activation (reset to default theory)^{19,31-33,37-39} or possibly by causing cytokine expression which decreases choroidal hyperpermeability.

In cases of recurrent CSC, increase of choroidal thickness preceded the symptomatic deterioration of vision and optical coherence tomography evidence of neurosensory detachment (Figure 1). The incidence of recurrence or persistent CSC was much higher in the observation group compared to the laser group at the end of six months (six recurrent cases and four persistent cases in the observation group versus one recurrent and four persistent cases in the laser group). This could again be indicative of the effect of laser in decreasing choroidal hyperpermeability through a mechanism not completely understood. Other studies have also shown that SDM laser decreases recurrences of CSC.¹²

Longer follow up of SDM-treated eyes will reveal the true recurrence rate and whether the effect of laser is long-lasting or not. Limitations of this study are a small sample size, short follow-up period and lack of microperimetric correlation.

Conclusion

SDM laser hastens visual rehabilitation quantitatively as well as qualitatively. It also reduces the chances of CSC going into chronicity and recurrence, compared to the current standard of care (observation). Since it has a high safety profile, SDM laser is recommended in acute CSC and in those cases of CSC where the angiographic leak is at a subfoveal location.

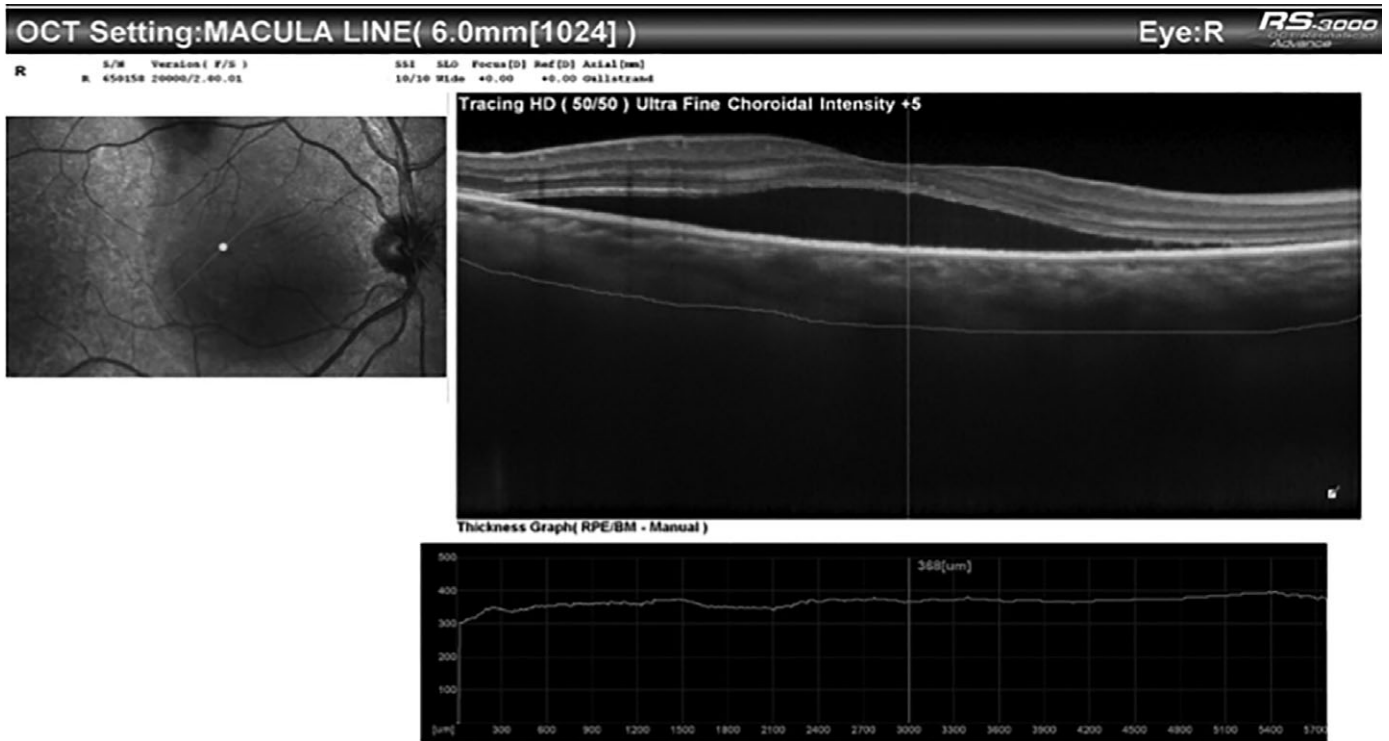

Figure 1. A: Right eye of a patient showing neurosensory detachment (NSD) at baseline

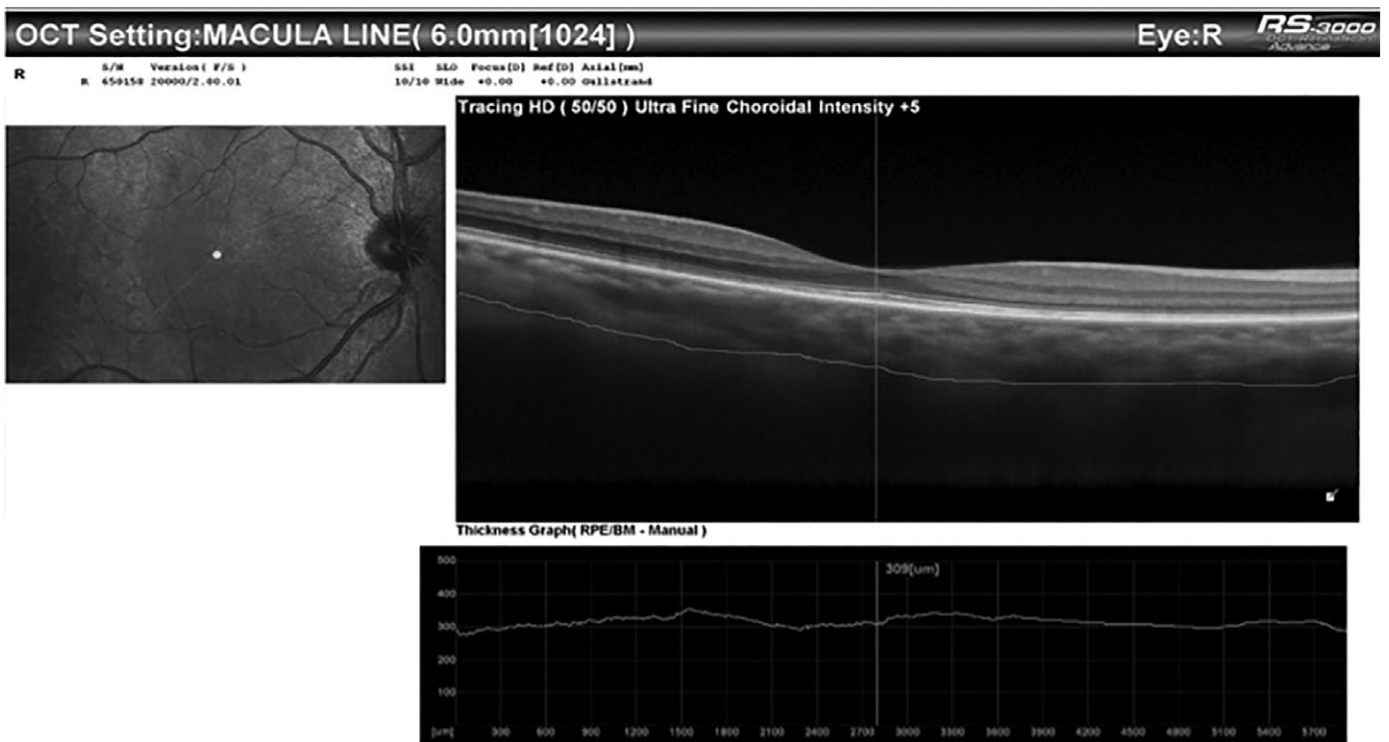
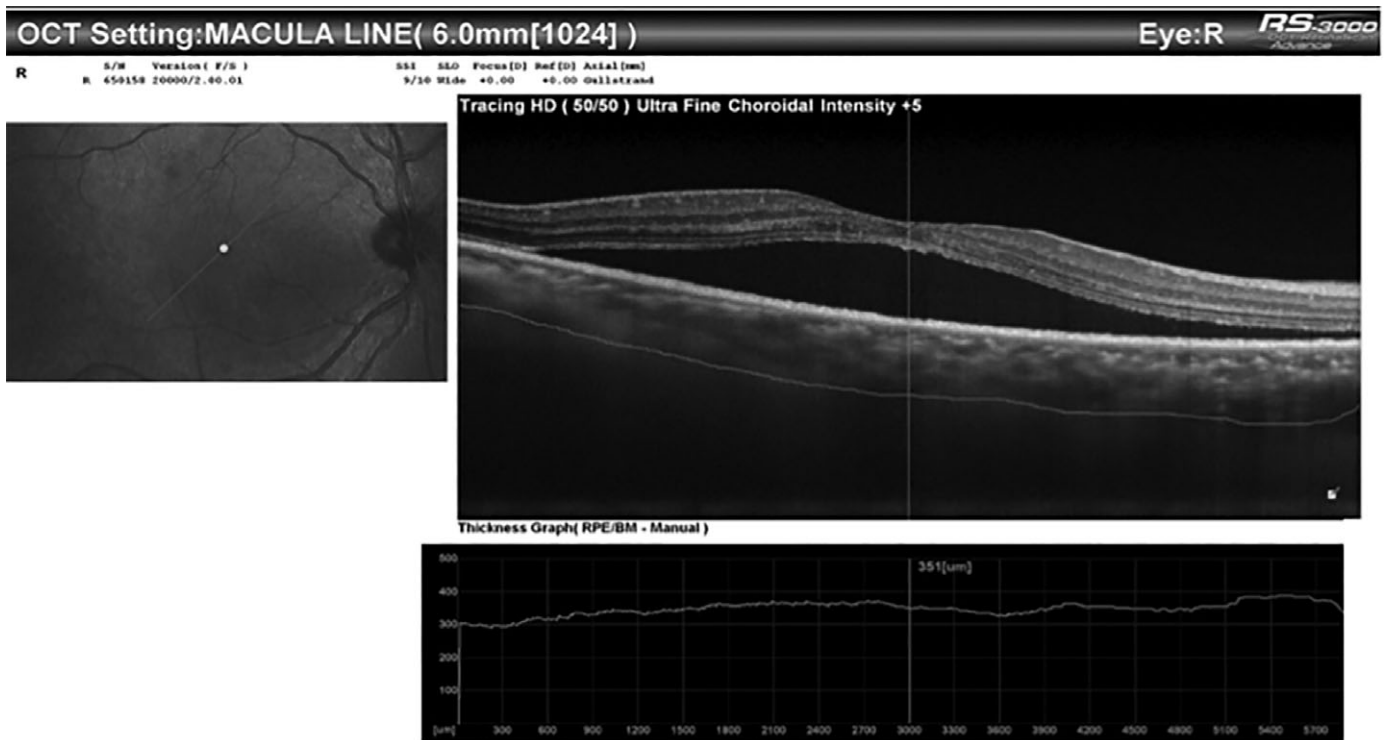
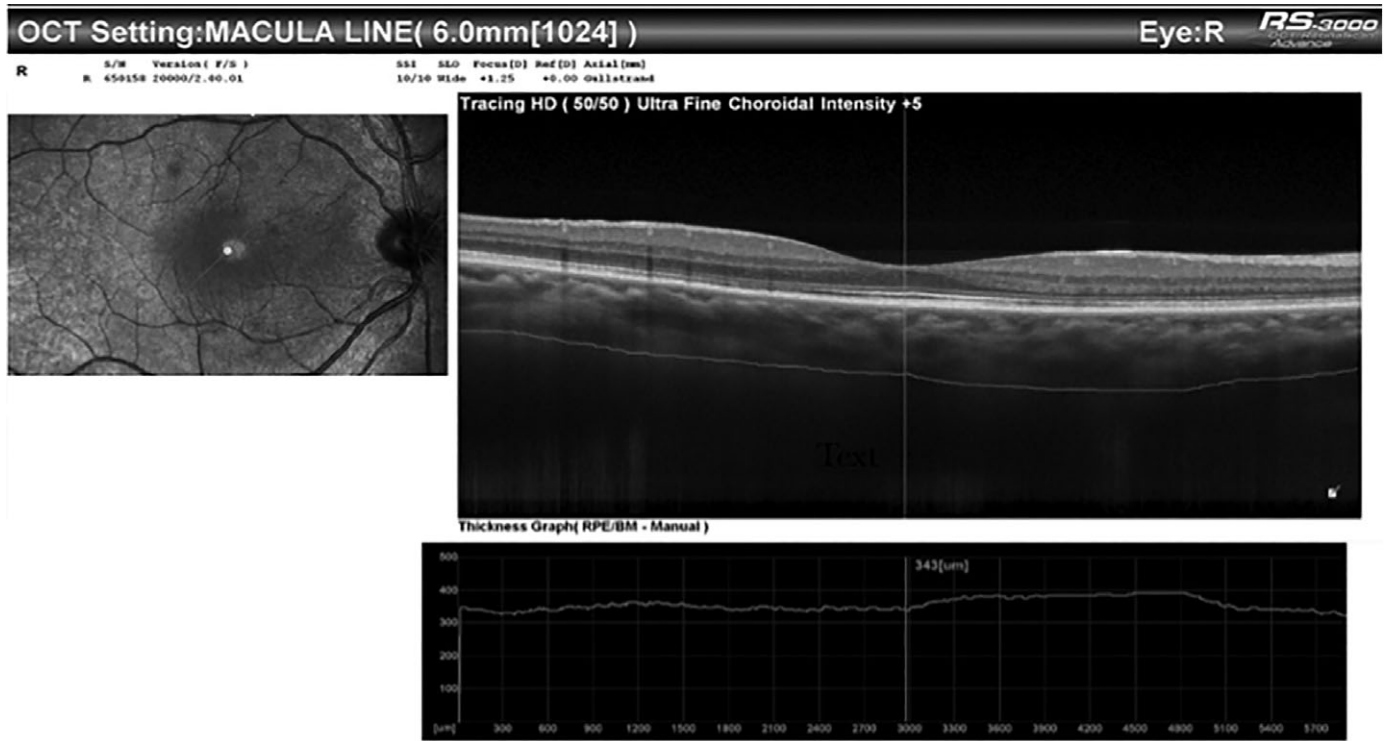

Figure 1. B: NSD resolution after four weeks of observation. Subfoveal choroidal thickness is 309 μ .



REFERENCES

- Spaide RF, Hall L, Haas A et al. Indocyanine green videoangiography of older patients with central serous chorioretinopathy. *Retina Phila Pa* 1996; 16: 203–213.
- Gass JD. Pathogenesis of disciform detachment of the neuroepithelium. *Am J Ophthalmol* 1967; 63: 1–139.
- Baran NV, Gürlü VP, Esgin H. Long-term macular function in eyes with central serous chorioretinopathy. *Clin Exp Ophthalmol* 2005; 33: 369–372.
- Cardillo Piccolino F, Eandi CM, Ventre L et al. Photodynamic therapy for chronic central serous chorioretinopathy. *Retina Phila Pa* 2003; 23: 752–763.
- Ma J, Meng N, Xu X et al. System review and meta-analysis on photodynamic therapy in central serous chorioretinopathy. *Acta Ophthalmol* 2014; 92: e594–e601.
- Robertson DM, Ilstrup D. Direct, indirect, and sham laser photocoagulation in the management of central serous chorioretinopathy. *Am J Ophthalmol* 1983; 95: 457–466.
- Nicholson B, Noble J, Forooghian F et al. Central serous chorioretinopathy: update on pathophysiology and treatment. *Surv Ophthalmol* 2013; 58: 103–126.
- Chen S-N, Hwang J-F, Tseng L-F et al. Subthreshold diode micropulse photocoagulation for the treatment of chronic central serous chorioretinopathy with juxtafoveal leakage. *Ophthalmology* 2008; 115: 2229–2234.
- Koss MJ, Beger I, Koch FH. Subthreshold diode laser micropulse photocoagulation versus intravitreal injections of bevacizumab in the treatment of central serous chorioretinopathy. *Eye Lond Engl* 2012; 26: 307–314.
- Behnia M, Khabazkhoob M, Aliakbari S et al. Improvement in visual acuity and contrast sensitivity in patients with central serous chorioretinopathy after macular subthreshold laser therapy. *Retina Phila Pa* 2013; 33: 324–328.
- Hata M, Oishi A, Shimozono M et al. Early changes in foveal thickness in eyes with central serous chorioretinopathy. *Retina Phila Pa* 2013; 33: 296–301.
- Gawęcki M, Jaszczuk-Maciejewska A, Jurska-Jasko A et al. Functional and morphological outcome in patients with chronic central serous chorioretinopathy treated by subthreshold micropulse laser. *Graefes Arch Clin Exp Ophthalmol* 2017; 255: 2299–2306.
- Arora S, Pyare R, Sridharan P et al. Choroidal thickness evaluation of healthy eyes, central serous chorioretinopathy, and fellow eyes using spectral domain optical coherence tomography in Indian population. *Indian J Ophthalmol* 2016; 64: 747–751.
- Brancato R, Pece A, Avanza P et al. Photocoagulation scar expansion after laser therapy for choroidal neovascularization in degenerative myopia. *Retina Phila Pa* 1990; 10: 239–243.
- Schatz H, Yannuzzi LA, Gitter KA. Subretinal neovascularization following argon laser photocoagulation treatment for central serous chorioretinopathy: complication or misdiagnosis? 1975. *Retina Phila Pa* 2012; 32: OP893–OP906.
- Schlötzer-Schrehardt U, Viestenz A, Naumann GO et al. Dose-related structural effects of photodynamic therapy on choroidal and retinal structures of human eyes. *Graefes Arch Clin Exp Ophthalmol* 2002; 240: 748–757.
- Lai TYY, Chan W-M, Lam DSC. Transient reduction in retinal function revealed by multifocal electroretinogram after photodynamic therapy. *Am J Ophthalmol* 2004; 137: 826–833.
- Tzekov R, Lin T, Zhang K-M et al. Ocular changes after photodynamic therapy. *Invest Ophthalmol Vis Sci* 2006; 47: 377–385.
- Sivaprasad S, Elagouz M, McHugh D et al. Micropulsed diode laser therapy: evolution and clinical applications. *Surv Ophthalmol* 2010; 55: 516–530.
- Luttrull JK. Low intensity/high density subthreshold diode micropulse laser for central serous chorioretinopathy. *Retina Phila Pa* 2016; 36: 1658–1663.
- Malik KJ, Sampat KM, Mansouri A et al. Low-intensity/high density subthreshold micropulse diode laser for chronic central serous chorioretinopathy. *Retina* 2015; 35: 532–536.
- Roisman L, Magalhães FP, Lavinsky D et al. Micropulse diode laser treatment for chronic central serous chorioretinopathy: a randomized pilot trial. *Ophthalmic Surg Lasers Imaging Retina* 2013; 44: 465–470.
- Kretz FT, Beger I, Koch F et al. Randomized clinical trial to compare micropulse photocoagulation versus half-dose verteporfin photodynamic therapy in the treatment of central serous chorioretinopathy. *Ophthalmic Surg Lasers Imaging Retina* 2015; 46: 837–843.
- Yadav NK, Jayadev C, Mohan A et al. Subthreshold micropulse yellow laser (577 nm) in chronic central serous chorioretinopathy: safety profile and treatment outcome. *Eye (Lond)* 2015; 29: 258–264.
- Lanzetta P, Furlan F, Morgante L et al. Nonvisible subthreshold micropulse diode laser (810 nm) treatment of central serous chorioretinopathy. A pilot study. *Eur J Ophthalmol* 2008; 18: 934–940.
- Ricci F, Missiroli F, Regine F et al. Indocyanine green enhanced subthreshold diode-laser micropulse photocoagulation treatment of chronic central serous chorioretinopathy. *Graefes Arch Clin Exp Ophthalmol* 2009; 247: 597–607.
- Gupta B, Elagouz M, McHugh D et al. Micropulse diode laser photocoagulation for central serous chorioretinopathy. *Clin Exp Ophthalmol* 2009; 37: 801–805.
- Breukink MB, Mohr JK, Ossewaarde van Norel A et al. Half dose photodynamic therapy followed by diode micropulse laser therapy as treatment for chronic central serous chorioretinopathy: evaluation of a prospective treatment protocol. *Acta Ophthalmol* 2016; 94: 187–197.
- Scholz P, Ersoy L, Boon CJF et al. Subthreshold micropulse laser (577 nm) treatment in chronic central serous chorioretinopathy. *Ophthalmologica* 2015; 234: 189–194.
- Gawęcki M. Increase in central retinal edema after subthreshold diode micropulse laser treatment of chronic central serous chorioretinopathy. *Case Rep Ophthalmol Med* 2015; 2015: 813414.
- Luttrull JK, Sramek C, Palanker D et al. Long-term safety, high-resolution imaging, and tissue temperature modeling of subvisible diode micropulse photocoagulation for retinovascular macular edema. *Retina Phila Pa* 2012; 32: 375–386.
- Luttrull JK, Sinclair SH. Safety of transfoveal subthreshold diode micropulse laser for fovea-involving diabetic macular edema in eyes with good visual acuity. *Retina Phila Pa* 2014; 34: 2010–2020.
- Luttrull JK, Dorin G. Subthreshold diode micropulse laser photocoagulation (SDM) as invisible retinal phototherapy for diabetic macular edema: a review. *Curr Diabetes Rev* 2012; 8: 274–284.
- Giovannini A, Scassellati-Sforzolini B, D'Alto Brandano E et al. Choroidal findings in the course of idiopathic serous pigment epithelium detachment detected by indocyanine green videoangiography. *Retina Phila Pa* 1997; 17: 286–293.
- Wong KH, Lau KP, Chhablani J et al. Central serous chorioretinopathy: what we have learnt so far. *Acta Ophthalmol* 2016; 94: 321–325.
- Maruko I, Iida T, Sugano Y et al. Subfoveal choroidal thickness in fellow eyes of patients with central serous chorioretinopathy. *Retina Phila Pa* 2011; 31: 1603–1608.
- Luttrull JK, Margolis BWL. Functionally guided retinal protective therapy for age-related macular and inherited retinal degenerations. A pilot study. *Invest Ophthalmol Vis Sci* 2016; 57: 265–275.
- Luttrull JK, Chang DB, Margolis BWL et al. Laser resensitization of medically unresponsive neovascular age-related macular degeneration: efficacy and implications. *Retina* 2015; 35: 1184–1194.
- Luttrull JK, Musch MC, Mainster MA. Subthreshold diode micropulse photocoagulation for the treatment of clinically significant diabetic macular edema. *Br J Ophthalmol* 2005; 89: 74–80.